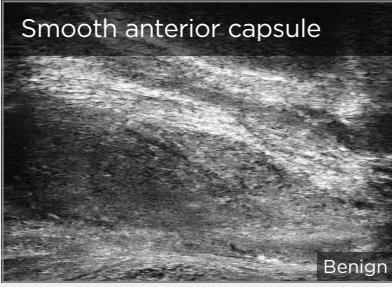
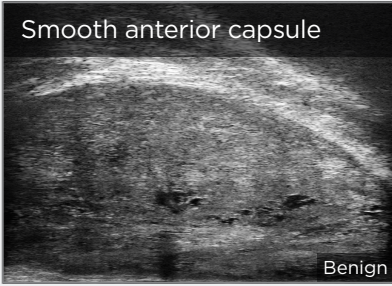
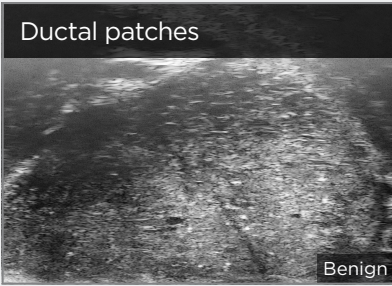
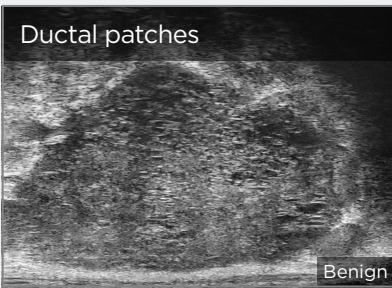
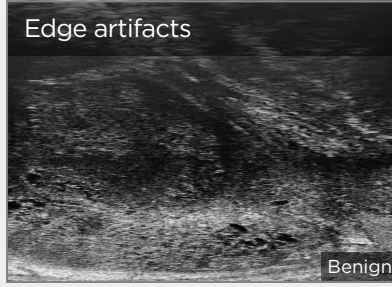
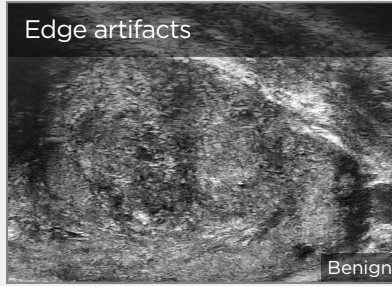
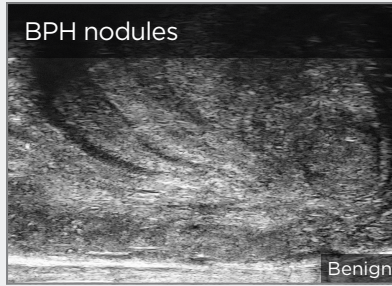
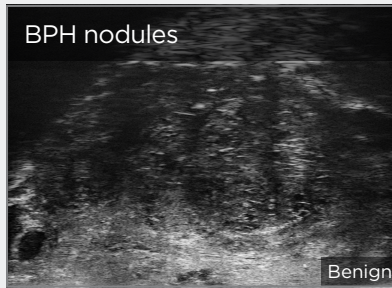


LOW-RISK FEATURES

Ductal Patches in Hyper or Hypoechoic Tissue

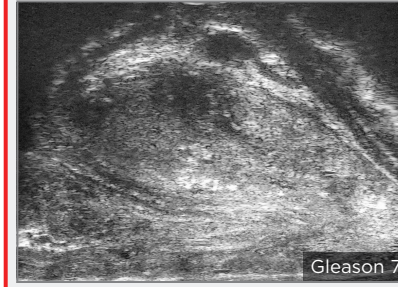
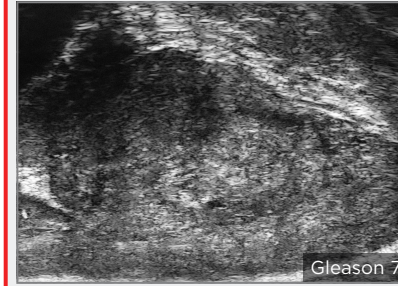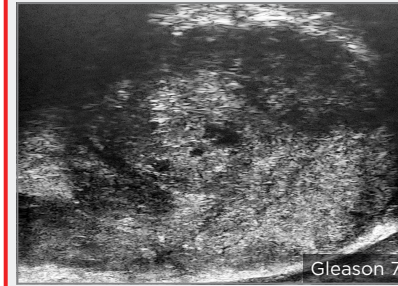
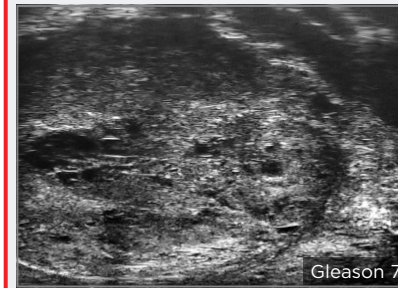


Pitfalls and Nodules

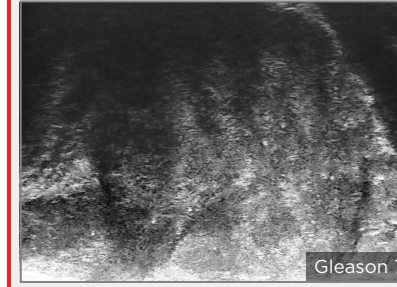
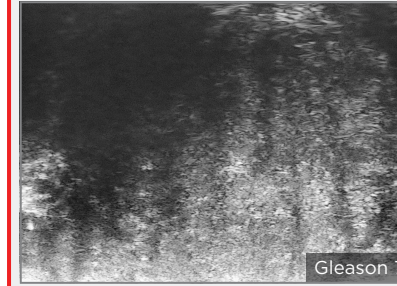
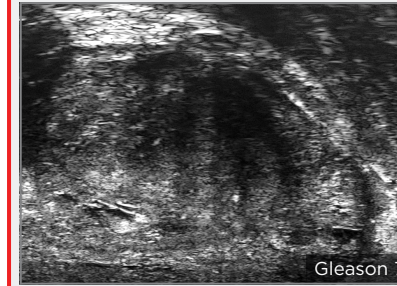



HIGH-RISK FEATURES (NO PARTICULAR ORDER OF RISK)

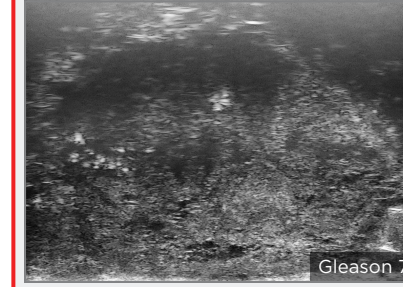

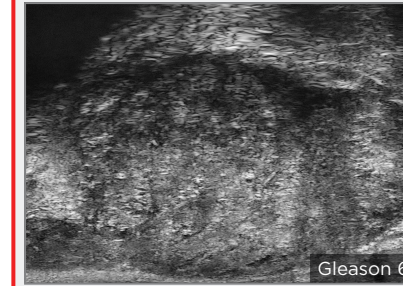
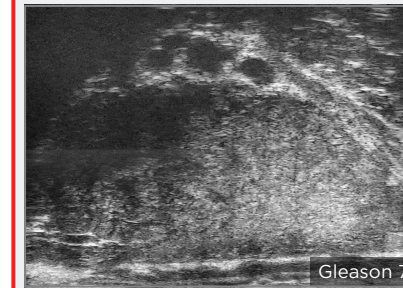
Focal Anterior Lesions



Hypoechoic Finger-like Projections



Storm-cloud



Lesions Occupying the Anterior Horn and Lateral Anterior Prostate

